

Subconjunctivally injected liposome encapsulated sirolimus and topical tacrolimus for the treatment of non-responsive keratoconjunctivitis sicca in the spontaneous dog model

Magda B. Gómez Guajardo¹, Mónica A. Linares-Alba², Joice Furtado Fonzar¹, Dennis E. Brooks³, Gustavo A. García Sánchez¹, María J. Bernad-Bernad^{2*} and Rodrigo G. Santisteban¹

*Correspondence: bernadf@comunidad.unam.mx



¹Veterinary Specialty Hospital "Oftalvet", Av. Coyoacán 1141, Benito Juárez, CP 03100, Mexico City, USA.

²Faculty of Chemistry, National Autonomous University of Mexico, Av. Universidad 3000, Coyoacán, CP 04510, Mexico City, USA.

³College of Veterinary Medicine, University of Florida, 2015 SW 16th Ave Gainesville, Florida, USA.

Abstract

Objective: The aim of this study was to evaluate the therapeutic utility of sirolimus liposomes (prepared by two different techniques at two different doses) by subconjunctival injection, and tacrolimus ophthalmic solution at 0.03% in canine patients diagnosed with keratoconjunctivitis sicca (KCS) non-responsive to conventional treatment.

Procedures: 20 privately owned pet dogs with clinically confirmed non-responsive KCS were randomized into 5 groups. Patients were administered with 0.15 ml of placebo or product respectively every 2 weeks for 60 days. Also, all patients received topically tacrolimus 0.03% solution 3 times a day for 90 days. Each animal was given a full ophthalmic examination prior and during the evaluation.

Results: During the evaluation, no adverse effects were observed. For a 0.16 mg/ml dose of sirolimus, the heating method provided liposomes with enhanced immunomodulating activity in contrast to the ethanol injection method. On the other hand, the improvement in lacrimal production achieved by a 0.4 mg/ml sirolimus dose was independent of the preparation technique. HM4 and EI16 formulations showed important decrease in secondary pigmentary keratitis. Also, the use of sirolimus liposomes exhibited reduction in corneal vascularization and conjunctival discharge.

Conclusions: The 0.4 mg/ml dose provided greater improvement of lacrimal production and minimization of ocular irritation indicators with no influence of the preparation technique used. The heating method generated liposomal dispersions with enhanced immunomodulating activity at a lower dose of 0.16 mg/ml. Besides lacrimal production improvement, the treatment significantly improved patient vision clarity.

Keywords: Sirolimus, liposome, tacrolimus, keratoconjunctivitis sicca, dogs

Introduction

The lacrimal functional unit is composed of the lacrimal glands, ocular surface and the interconnecting innervation [1,2]. Deficiencies in any of the tear film layers, defective spreading of tear film, systemic diseases, and some medications can disturb the unit and cause dry eye disease. Aqueous layer deficiency is the most common cause, usually caused by decreased tear secretion. Causes of this include Sjögren's syndrome (SS), senile hyposecretion, lacrimal gland excision, vitamin A deficiency, etc [3].

The development of animal models with affectation of the lacrimal functional unit in a similar manner to the effect seen in human dry eye disease, is beneficial for determining the multiple mechanisms occurring in the pathogenesis of dry eye [1]. Canine dry eye cases show similarities with human SS, specifically on immune mediated destructive changes of the lacrimal gland and hormonal involvement [4]. Keratoconjunctivitis sicca (KCS) as SS, presents female predominance suggesting that androgens have an effect on lacrimal gland

size and function and on autoimmunity. Also, incidence of KCS is higher in older dogs (7-9 years) and approximately 70 % of KCS cases in the dog eventually become bilateral [5].

Keratoconjunctivitis sicca, commonly called dry eye syndrome, can be defined as a progressive inflammatory condition of the cornea and conjunctiva caused by tear deficiency [5]. There are several known causes of KCS but in dogs is most often immune mediated due to disruption of the blood-tear barrier, that allows immune destruction of: lacrimal acinar epithelial cells, lacrimal glands, salivary glands, and gland of the third eyelid [7].

Treatment for KCS includes anti-inflammatory drugs, antibiotics, artificial tears and stimulants of the natural tear production by immunomodulatory drugs (cyclosporine, tacrolimus, sirolimus, etc.) and cholinergics (pilocarpine). Nevertheless, stimulation of natural tear production using immunomodulatory drugs seems to provide the greatest improvement in clinical signs and prevention of visual loss [7]. The success of ocular therapy in animals will also depend on the drug delivery system and the convenience of application of the ophthalmic medication by the animal's owner. Frequent applications are often inconvenient for the owner, resulting in poor treatment compliance [4]. Given the current treatment options, poor compliance or low patient acceptance of therapy are the primary causes of visual impairment in KCS [8].

Sirolimus is an immunosuppressive agent. It is a macrocyclic lactone produced by *Streptomyces hygroscopicus* [9]. It blocks T lymphocyte proliferation induced by stimuli employing either Ca²⁺-dependent or Ca²⁺-independent pathways. Its effects are not limited to IL-2- or IL-4 mediated growth of T cells, as it has been found to inhibit IL-12, IL-7, and IL-15 driven proliferation of activated T cells. Sirolimus blocks cell cycle progression in mid-to-late G₁ phase. It also prevents IL-2 or IL-6 dependent differentiation into antibody-producing cells, thereby decreasing IgM, IgG and IgA production [10]. In this way, sirolimus mechanism of action is distinct from that of other immunosuppressants [9]. For instance, Shah et al demonstrated that the topical administration of sirolimus suppresses lacrimal gland inflammation in the male non-obese diabetic mouse model of SS [11].

Sirolimus is a substrate for both cytochrome P450 IIIA4 (CYP3A4) and P-glycoprotein. Therefore, drugs that affect this isoenzyme may influence absorption and the subsequent elimination of systemically absorbed sirolimus. Inhibitors of CYP3A4 may decrease the metabolism of sirolimus and increase sirolimus levels, while inducers of CYP3A4 may increase the metabolism of sirolimus and decrease sirolimus levels [9]. For example, simultaneous administration with Cyclosporine A capsules (Neoral[®]), the mean C_{max} and AUC of sirolimus were increased by 116% and 230%, respectively, relative to administration of sirolimus alone. After multiple-dose administration of sirolimus given 4 hours after Neoral[®], cyclosporine oral-dose clearance was reduced, and lower doses were needed to maintain target cyclosporine concentration [12].

Despite of above mentioned advantages, sirolimus is a very hydrophobic drug, practically insoluble in water. Consequently, clinically and commercially acceptable topical formulations have been difficult to prepare. We propose a liposomal formulation, which is a biocompatible and biodegradable drug delivery system, as a strategy for controlling and obtaining local drug release, the formulation comprises the use of environmental-sensitive liposomes to *in situ* triggers (chemical and enzymatic) in the target site.

In this case, the intelligent system is triggered by endogenous phospholipase A2 (PLA2), which is found in elevated concentrations in dry eye disease [13-15]. PLA2-catalyzed degradation of the liposomes leads to a site-specific release and absorption of the encapsulated drug at the target site [16-19]. An additional advantage is that when the liposomal membrane is destabilized, lysolipids and free fatty acids are generated at the same time in local high concentrations. It is expected that the generated lysolipids and fatty acids act as permeability enhancers and therefore increase drug transport across the biological membrane [18,19].

Besides that, the diseased eye environment is mainly known for its hyperosmolarity [13]. Hyperosmotic stress increase levels of reactive oxygen species (ROS) and this are another specific environmental trigger. ROS interacts with unsaturated fatty acids in the vesicle bilayer causing lipid peroxidation. With the peroxidation, lysophospholipids are formed and then, bilayer disruption happens and so drug delivery occurs [20,21]. thus, the formulation is expected to be an intelligent system with a dual environmental trigger, phospholipase A2 and ROS.

The aim of this study was to evaluate the therapeutic utility of a new medication consisting of sirolimus loaded liposomes by subconjunctival injection, followed by topical application of tacrolimus ophthalmic solution at 0.03% in canine patients diagnosed with KCS that do not respond to conventional treatment with cyclosporine A or tacrolimus. Stimulation of lacrimal gland added to an enhanced dosing profile could be useful to improve the treatment of dry eye and prevent surgical intervention.

Materials and methods

All materials were used as received. Sirolimus liposomal formulations were obtained from Laboratorio Santgar (Mexico City, Mexico); Bio Glo TM Sterile Strips 1 mg Fluorescein sodium Ophthalmic Strip USP and Tear Flo Tear Measurement Strip from HUB Pharmaceuticals, (Rancho Cucamonga, USA); Portable Slit Lamp Kowa SL-15 from Kowa American Corporation, (Vermont, USA); Indirect Ophthalmoscope Keeler All Pupil II from Keeler Ophthalmic Instruments, (Bromall, USA); Volk Double Aspheric 20D from USA Volk Optical, (Ohio, USA); Terumo Syringe Tuberculin 1cc/ml 25G x 16mm (Batch: 140831D, Exp. Date: 07/2019) from Terumo Corporation, (Tokyo, Japan); BD Precision Glide TM Needle 30G x ½ (Batch: 4032464, Exp. Date: 03/2019) Becton Dickinson and Company, (Columbus, USA);

Eye Wash Sterile Isotonic Buffered Solution (Batch: 14290, Exp. Date: 09/2017), Altaire Pharmaceuticals, (New York, USA); Tono – Pen Vet Reichert Ophthalmic Instruments, Reichert, Inc. (New York, USA).

Formulations

The medications consisted of liposomes loaded with sirolimus with the formulation composition and preparation technique disclosed in **Table 1**. Control group was administered with placebo formulation consisting of all the excipients of the loaded formulations but the therapeutic agent. All subjects were administered topically with an ophthalmic immunosuppressant solution consisting of tacrolimus in olive oil at a 0.03% concentration.

Table 1. Liposomal formulations.

Formulation code	Composition	Preparation technique	Sirolimus dose (mg/mL)
HM16	Lecithin : Cholesterol (6:1 molar ratio) Sucrose 8.7 %	Modified heating method	0.16
HM4			0.4
Empty	Lecithin : Cholesterol (6:1 molar ratio)	Ethanol injection	0
EI16			0.16
EI4			0.4

HM16: Liposomes loaded with 0.16 mg/ml of sirolimus by the modified heating method.

HM4: Liposomes loaded with 0.4 mg/ml of sirolimus by the modified heating method.

EI16: Liposomes loaded with 0.16 mg/ml of sirolimus by ethanol injection.

EI4: Liposomes loaded with 0.4 mg/ml of sirolimus by ethanol injection.

Animals

Dogs with previously diagnosed KCS, nonresponsive to traditional immunosuppressant medication (Cyclosporine A or tacrolimus topical ophthalmic solution) were selected as the animal model for in vivo study.

Subject population

20 privately owned pet dogs with previously treated and clinically confirmed KCS were randomized into this study. Pretreatment evaluation included complete ophthalmoscopic examination, ocular irritation (evaluated using modified McDonald-Shadduck performance score), Schirmer tear test score and tear film break up time measurement [22].

Eligible dogs

Dogs previously diagnosed with chronic keratoconjunctivitis sicca who had not responded to conventional medical treatment. They must have presented values of Schirmer tear test below 5 mm/min and/or clinical signs such as: ocular discomfort, eye discharge, corneal opacity, ulceration and decreased vision. They were free of complicating concurrent disease. Were excluded those patients whose eye condition

was so serious that subconjunctival administration was contraindicated or was urgent the transposition of parotid ducts. Each dog's owner signed informed consent and agreement forms prior to entry.

Randomization

Dogs were randomized to receive one of the previously described formulations. Group assignment was performed by a person outside the medical team. Patients were distributed through balanced block randomization to one of four study groups or control group. Patients were numbered consecutively according to the date of to the study. Treatments were assigned by ascending number of patient, following the alphabetical order of the group formulation code. The identity of the medication administered to each study group remained unknown for the medical team until the analysis of results.

Treatment

All patients were administered with 0.15 ml of product, equivalent to a dose of 0.024 or 0.06 mg of sirolimus respectively. Control groups received 0.15 mL of placebo. The product was administered by subconjunctival injection (under topical anesthesia) by qualified personnel and was repeated every 2 weeks for 60 days. Also, every patient received topically tacrolimus 0.03% solution 3 times a day for 90 days.

Evaluation

Each animal was given a full ophthalmoscopic examination using direct and indirect ophthalmoscopy together with slit-lamp biomicroscopy. Tear production was evaluated using commercial standard Schirmer tear test strips. The strip was inserted in the lower conjunctival fornix of the eye and the length of tear wetting during one minute determined, results are reported as millimeters wetted by minute (mm/min). Intraocular pressure and tear film break up time were also determined. At each subsequent visit and before the next application of treatment, patients will undergo a complete examination (ophthalmoscopic examination, tear production evaluation, intraocular pressure determination, tear film break up time measurement and ocular irritation scored by the modified McDonald-Shadduck scoring system).

Data analysis

Statistical analysis was performed using statistical software (StatPlus:mac Pro, AnalystSoft Inc., Walnut CA). Twelve parameters were evaluated (including all items in the modified McDonald-Shadduck scoring system, STT I, STT II and TBUT to determine if there was a significant difference in the parameters over time, a one-way ANOVA with repeated measures was performed; a $p < 0.05$ was considered to be significant. To assess if there were significant differences between the dose levels, the data for each parameter/treatment group were pooled. Then, a one-way ANOVA was performed; a $p < 0.05$ was considered to be significant. Post-hoc analysis

was accomplished via the Tukey-Kramer test; a $p < 0.05$ was considered to be significant. Finally, a one-way ANOVA was utilized to determine if there were differences between the pooled data for the ethanol injection method versus the heating method; a $p < 0.05$ was considered to be significant.

Results

During the 90 days of evaluation, no adverse effects were reported by the owners or noted on ophthalmic examinations. One patient (2 dry eyes) was lost and replaced with another patient in the same study group; 20 patients completed the 90 day evaluation period. Increases in STT I and STT II values after the 60 day period of treatment versus the results obtained prior the subconjunctival injections were compared (Figure 1).

Results of tear production tear film stability and ocular irritation indicators were treated to find statistical significance among doses, and preparation technique used. Tables 2 to 4 summarize the statistical outcomes.

Discussion

The Schirmer Tear Test (STT) is the standard evaluation of quantitative tear production. Two types of STTs have been reported in dogs (abbreviated as STT 1 and STT 2), the STT 1 measures reflex aqueous tear production and the STT 2 measures the basal tear production after topical anesthetic is applied [2]. A diagnosis of KCS in the dog is made when a

measurement of < 10 mm/min of STT1 is found (the normal value is usually 16-24 mm/min) in association with typical clinical manifestations [5]. In normal dogs, the STT2 (following topical anaesthesia) is 11.6 ± 6.1 mm/min [6]. Qualitative tear film abnormalities can be diagnosed by measuring tear film breakup time (TBUT), normal TBUT is approximately 20 seconds. Mucin deficiencies manifest with tear film breakup times of less than 5 seconds in dogs and cats [2].

According to the presented results, tear production enhancement was observed in all groups after 5 injections of liposomal formulations treatment (Figure 1). Statistical analysis of tear production after treatment is reported in Table 2. For the heating method prepared formulations, the improvement was statistically significant only for the STT1 between both sirolimus loaded formulations compared with placebo. There was no difference in the improvement of tear production between HM16 and HM4. In the ethanol injection formulations case, both tested doses produced significant augmentation of basal tear production compared with empty liposomes. Nevertheless, there was no difference between doses. Only EI4 formulation produced significant improvement in total tear production.

About TBUT results, a significant increase was observed only with the use of EI4 liposomes. Though, we cannot directly correlate the obtained results with tear film stability because the test was not representative for up to 10 patients. They

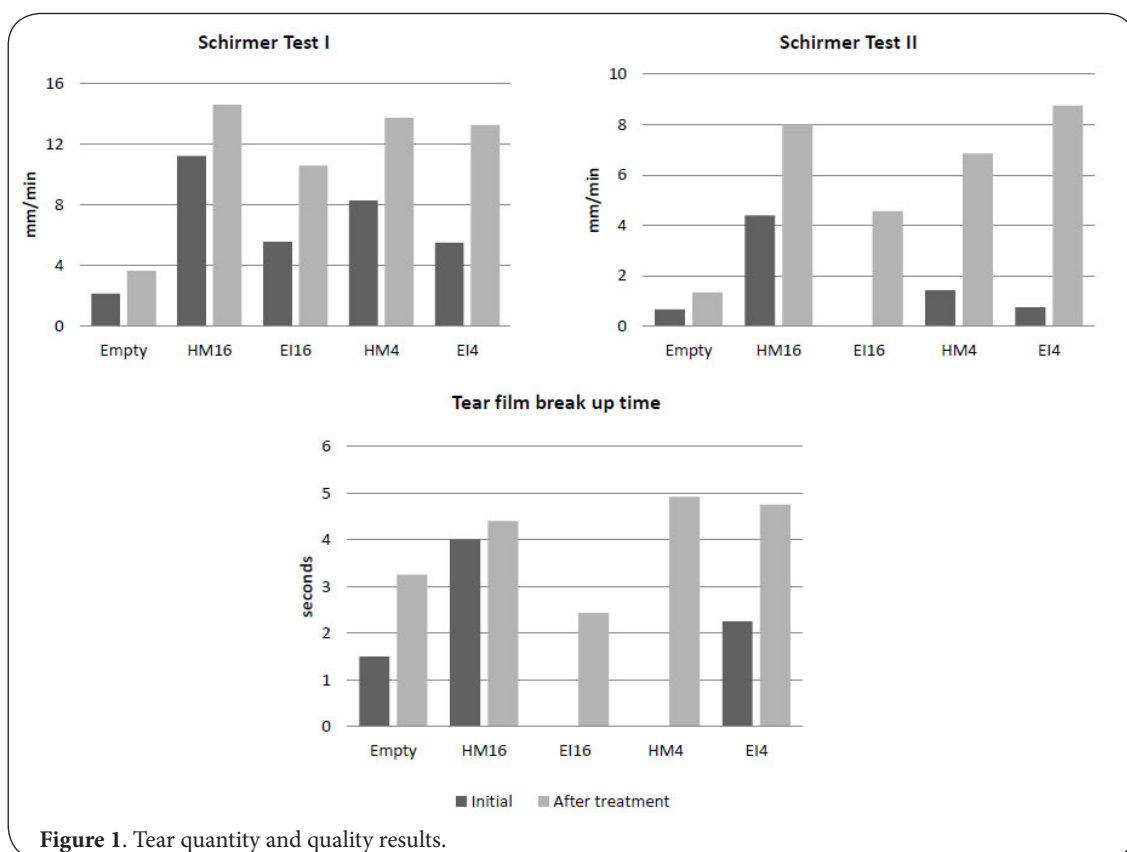


Figure 1. Tear quantity and quality results.

Table 2. Statistical comparison of sirolimus dose effect.

	Test	Formulation			ANOVA <i>p</i> -value	Tukey-Kramer <i>p</i> -value
		Empty (A)	0.16 mg/ml (B)	0.4 mg/ml (C)		
Heatingmethod	STTI (mm/min)	8.57 ± 4.45	12.60 ± 4.61	11.79 ± 4.65	< 0.002	A vs B <0.01 A vs C <0.05
	STTII (mm/min)	3.90 ± 3.08	5.50 ± 2.93	4.95 ± 4.96	Not significant	--
	TBUT (sec)	4.36 ± 1.63	4.72 ± 1.93	3.48 ± 3.37	Not significant	--
Ethanol injection	STT1 (mm/min)	3.86 ± 4.83	9.26 ± 5.55	10.92 ± 6.18	< 0.001	A vs C < 0.05
	STT2 (mm/min)	0.60 ± 1.48	2.10 ± 2.97	5.17 ± 4.30	<0.001	A vs B <0.01 A vs C <0.01
	TBUT (sec)	2.80 ± 2.48	1.83 ± 2.13	4.65 ± 2.46	0.001	A vs C <0.05 B vs C <0.01

Data is average ± standard deviation

ANOVA: Analysis of variance; STTI: Schirmer test I; STTII: Schirmer test II; TBUT: Tear film break up time

had ocular surface conditions (such as recent conjunctival flap and blepharospasm) that precluded the test, or were uncooperative during medical evaluation. Due to the randomization applied, these patients were assigned unevenly among groups. The small increase in lacrimal production and tear film stability observed in the placebo group is probably due to the presence of permeability enhancers produced by local destabilization of empty liposomes, thus improving topical tacrolimus permeation.

According to irritation indicators evaluated, there was statistical significant decrease in many parameters (Table 3). For vision clarity, of all formulations HM4 and EI16 showed greater gain in clarity. In the case of corneal vascularization, sirolimus loaded formulations exhibited reduction versus empty liposomes; besides with heating prepared liposomes the reduction was dose dependent. Conjunctival discharge was significant diminished by both HM formulations and IE16 compared with placebo. Noteworthy, the above mentioned results were analyzed separately between formulations prepared by the same technique.

Since results imply differences between formulations

loaded with the same amount of sirolimus, results between one technique and the other were compared (Table 4). For a 0.16 mg/ml dose of sirolimus, the heating method provided liposomes with enhanced immunomodulating activity in contrast to the ethanol injection method. On the other hand the improvement in lacrimal production achieved by a 0.4 mg/ml sirolimus dose was independent of the preparation technique. Most ocular irritation parameters showed the same trend, being significantly different at the lower dose but equal at the higher. Thus, the heating method apparently preserves the therapeutic activity of the drug better than the ethanol injection technique at lower concentrations; may be due to a superior drug entrapment. Probably, for the 0.4 mg/ml dose formulations the amount of sirolimus is so high that even if some of the drug is lost, a sufficient quantity of active drug remains to yield the therapeutic effect.

Some of examples of clinical improvement are showed in Figures 2 through 4. Figure 2 shows the clinical evolution of patient 9. The right eye of this patient with chronic KCS presented abundant mucopurulent discharge, hyperemic conjunctiva, corneal neovascularization and extensive pigmen-

Table 3. Indicators of ocular irritation with significant difference after treatment.

Technique	Parameter of the McDonald-Shadduck scoring system	Formulation			ANOVA <i>p</i> -value	Tukey-Kramer <i>p</i> -value
		Empty (A)	0.16 mg/ml (B)	4 mg/ml (C)		
Modified heating method	Vision Clarity	1.44 ± 1.04	0.88 ± 1.24	1.71 ± 1.43	<0.05	B vs C < 0.05
	Corneal Vascularization	1.40 ± 0.58	0.40 ± 0.50	0.91 ± 0.85	< 0.001	A vs B <0.01 A vs C <0.05 B vs C < 0.05
	Conjunctival Discharge	1.68 ± 1.14	0.60 ± 0.65	0.94 ± 1.00	< 0.001	A vs B <0.01 A vs C < 0.05
Ethanol injection	Vision Clarity	1.94 ± 1.24	2.49 ± 1.31	0.65 ± 0.75	<0.001	A vs C <0.01 B vs C <0.01
	Corneal Vascularization	1.42 ± 0.91	0.66 ± 0.48	0.90 ± 0.31	<0.001	A vs B <0.01 A vs C <0.05
	ConjunctivalDischarge	1.75 ± 1.18	0.97 ± 1.04	1.10 ± 1.25	<0.02	A vs B < 0.05

Data is average ± standard deviation

Table 4. Preparation technique comparison.

Test	Dose (mg/mL)	Ethanol Injection	Heating Method	ANOVA p-Value
STT1 (mm/min)	0.16	9.26 ±5.55	12.60 ±4.61	< 0.001
	0.4	10.92 ±6.18	11.79 ±4.65	Not Significant
STT2 (mm/min)	0.16	2.10 ±2.97	5.50 ±2.93	< 0.001
	0.4	5.17±4.30	4.95 ±4.96	Not Significant
TBUT (seconds)	0.16	1.83 ±2.13	4.72 ±1.93	< 0.001
	0.4	4.65 ±2.46	3.48 ±3.37	Not Significant

Data is average ± standard deviation
 ANOVA: Analysis of variance; STTI: Schirmer test I
 STTII: Schirmer test II; TBUT: Tear film break up time

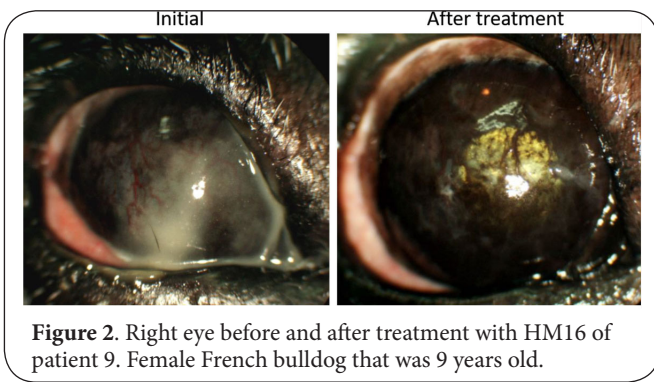


Figure 2. Right eye before and after treatment with HM16 of patient 9. Female French bulldog that was 9 years old.

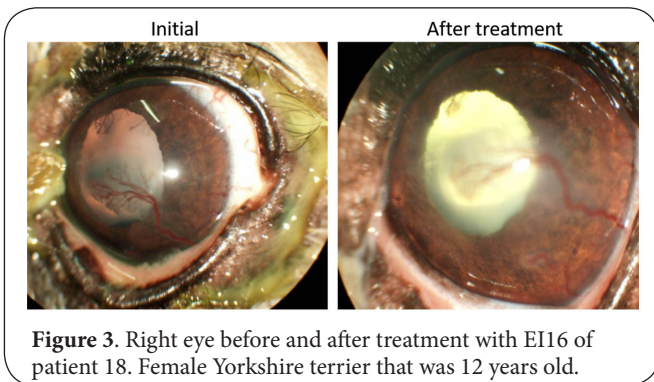


Figure 3. Right eye before and after treatment with EI16 of patient 18. Female Yorkshire terrier that was 12 years old.

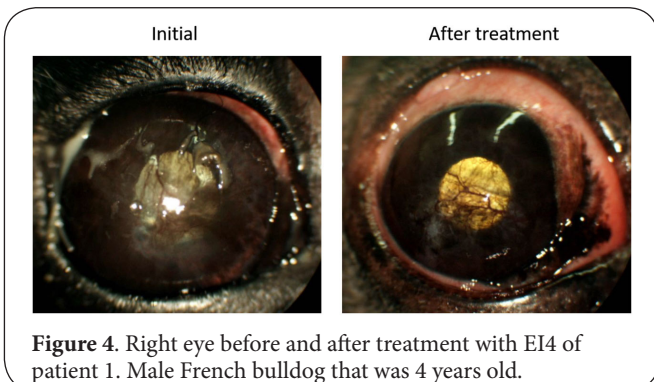


Figure 4. Right eye before and after treatment with EI4 of patient 1. Male French bulldog that was 4 years old.

tary keratitis. Corneal opacity made it impossible to observe the anterior chamber and the pupila at the beginning of the study. After the last application of HM16 patient outcome was favorable, no eye discharge was observed, the cornea had a more uniform and smooth, even brilliant appearance, we were able to see the anterior chamber, pupil and even tapetal reflection is observed. STT1 result of this patient was triplicated at the end of the study.

Improvement of patient 18 is shown in **Figure 3**. The patient presented extensive dried eyelid exudate, mucopurulent ocular discharge, moderate conjunctival hyperemia and corneal neovascularization. Although the cornea was bright, the ophthalmologist could see clinical signs of chronicity. After treatment the eye of the patient had a more uniform corneal surface, less neovascularization and notably less ocular mucopurulent discharge. STT1 value for this patient augmented 10 mm/min from the initial value with the application of EI16 treatment, even when owner compliance to the application of tacrolimus solution at home was poor.

Figure 4 presents the aspect of the right eye of a male French bulldog with chronic KCS. In the initial image, we can note the marked conjunctival hyperemia, lackluster appearance of the corneal surface, superficial corneal neovascularization and mucopurulent discharge. Pigmentary keratitis was also observed. After the last application of EI4, the corneal surface was observed bright, without secretion and the conjunctiva had better appearance. Pigmentary keratitis lowered and was only observed in the ventral portion of the cornea.

It is noteworthy that subconjunctival application of sirolimus (independently of dose or preparation technique) decreased pigmentary keratitis quite a bit for those patients that presented it at the beginning of the study. Owners of this patients reported that dogs vision was better, noted as a reduction on mobility limitation observed previously. Removing pigment from the cornea is very difficult and it remains to be studied if the pigment returns after stopping sirolimus medication. However, during this study sirolimus application improved considerably patients vision clarity, even in patients that were severely visual impaired.

Correlating the described results, the 0.4 mg/ml dose provided greater improvement of lacrimal production and minimization of ocular irritation indicators with no influence of the preparation technique used. Also, the heating method generated liposomal dispersions with enhanced immunomodulating activity at a lower dose of 0.16 mg/ml. Coupled with lacrimal production improvement, the subconjunctival application of sirolimus significantly decreased pigmentary keratitis improving considerably patient vision clarity.

Competing interests

The authors declare that they have no competing interests.

Acknowledgements

Authors would like to thank all of the staff of Oftalvet Veterinary Specialty Hospital, their work made our research

possible. Also, we would like to thank Laboratorio Santgar for have kindly provided the formulations samples.

Authors' contributions

Authors' contributions	MBG	MAL	JF	DEB	GAG	MJB
Research concept and design	--	✓	--	--	✓	✓
Collection and/or assembly of data	✓	✓	--	--	✓	--
Data analysis and interpretation	✓	--	✓	--	--	--
Writing the article	✓	✓	✓	--	--	--
Critical revision of the article	--	--	✓	✓	✓	✓
Final approval of article	--	--	--	✓	✓	✓
Statistical analysis	--	--	--	✓	--	--

Publication history

Editor: Franz-Josef Kaup, German Primate Center, Germany.
Received: 27-Nov-2017 Final Revised: 20-Dec-2017
Accepted: 02-Jan-2018 Published: 21-Jan-2018

References

1. Stern ME, Gao J, Siemasko KF, Beuerman RW and Pflugfelder SC. **The role of the lacrimal functional unit in the pathophysiology of dry eye.** *Exp Eye Res.* 2004; **78**:409-16. | [PubMed](#)
2. Grahn BH and Storey ES. **Lacrimostimulants and lacrimomimetics.** *Vet Clin North Am Small Anim Pract.* 2004; **34**:739-53. | [Article](#) | [PubMed](#)
3. Rolando M and Zierhut M. **The ocular surface and tear film and their dysfunction in dry eye disease.** *Surv Ophthalmol.* 2001; **45 Suppl 2**:S203-10. | [Article](#) | [PubMed](#)
4. Rathbone MJ and Gurny R. **Controlled release veterinary drug delivery: biological and pharmaceutical considerations.** *Elsevier, Amsterdam.* 2000; 123-124.
5. Martin CL. **Ophthalmic disease in veterinary medicine.** *CRC Press.* 2009.
6. Barabino S, Chen W and Dana MR. **Tear film and ocular surface tests in animal models of dry eye: uses and limitations.** *Exp Eye Res.* 2004; **79**:613-21. | [Article](#) | [PubMed](#)
7. Berdoulay A, English RV and Nadelstein B. **Effect of topical 0.02% tacrolimus aqueous suspension on tear production in dogs with keratoconjunctivitis sicca.** *Vet Ophthalmol.* 2005; **8**:225-32. | [Article](#) | [PubMed](#)
8. Maggs DJ, Miller P and Ofri R. **Slatter's fundamentals of veterinary ophthalmology. 4th edition.** *Elsevier Health Sciences, China.* 2012; 166-169.
9. DOSAGE AND ADMINISTRATION [Internet]. **Rapamune (sirolimus) Oral Solution and Tablets.** [cited 2015Sep12]. | [Article](#)
10. Sehgal SN. **Rapamune®(RAPA, rapamycin, sirolimus): mechanism of action immunosuppressive effect results from blockade of signal transduction and inhibition of cell cycle progression.** *Clinical biochemistry.* 1998; **31**:335-40.
11. Shah M, Janga SR, Edman MC, Meng Z, Chen J, Ma T, Klingamm W, Ding C, MacKay JA and Hamm-Alvarez SF. **Topical Rapamycin suppresses lacrimal gland inflammation in a mouse model of Sjögren's Syndrome.** *Investigative Ophthalmology & Visual Science.* 2015; **56**:4810.
12. Smith S. **ImmunoTherapeutics: Market Overview (2009-2014).** *Xlibris Corporation.* 2011.
13. Wei Y and Asbell PA. **The core mechanism of dry eye disease is inflammation.** *Eye Contact Lens.* 2014; **40**:248-56. | [Article](#) | [PubMed Abstract](#) | [PubMed FullText](#)
14. Wei Y, Du Z, Chen D, Afreen J, Chen V and Asbell P. **The role of the secretory group IIa phospholipase A2 (sPLA2-IIa) in ocular surface inflammation.** *JSM Ophthalmology.* 2013; **1**:1005.
15. Chen D, Wei Y, Li X, Epstein S, Wolosin JM and Asbell P. **sPLA2-IIa is an inflammatory mediator when the ocular surface is compromised.** *Exp Eye Res.* 2009; **88**:880-8. | [Article](#) | [PubMed Abstract](#) | [PubMed FullText](#)
16. Morgado MA, Cabral JM and Prazeres DM. **Phospholipase A2-catalyzed**

hydrolysis of lecithin in a continuous reversed-micellar membrane bioreactor. *Journal of the American Oil Chemists' Society.* 1996; **73**:37-46.

17. Vermehren C, Kiebler T, Hylander I, Callisen TH and Jorgensen K. **Increase in phospholipase A2 activity towards lipopolymer-containing liposomes.** *Biochim Biophys Acta.* 1998; **1373**:27-36. | [Article](#) | [PubMed](#)
18. Hoyrup P, Mouritsen OG and Jorgensen K. **Phospholipase A(2) activity towards vesicles of DPPC and DMPC-DSPC containing small amounts of SMPC.** *Biochim Biophys Acta.* 2001; **1515**:133-43. | [Article](#) | [PubMed](#)
19. Davidsen J, Vermehren C, Frokjaer S, Mouritsen OG and Jorgensen K. **Drug delivery by phospholipase A(2) degradable liposomes.** *Int J Pharm.* 2001; **214**:67-9. | [Article](#) | [PubMed](#)
20. Vossen RC, van Dam-Mieras MC, Hornstra G and Zwaal RF. **Continuous monitoring of lipid peroxidation by measuring conjugated diene formation in an aqueous liposome suspension.** *Lipids.* 1993; **28**:857-61. | [PubMed](#)
21. Chatterjee SN and Agarwal S. **Liposomes as membrane model for study of lipid peroxidation.** *Free Radic Biol Med.* 1988; **4**:51-72. | [Article](#) | [PubMed](#)
22. Hackett RB and McDonald TO. **Eye irritation. In: Advances in Modern Toxicology: Dermatoxicology.** (eds. Marzulli F and Maibach H) Hemisphere Publishing Corporation, New York. 1991; 749-815.

Citation:

Gómez Guajardo MB, Linares-Alba MA, Furtado Fonzar J, Brooks DE, García Sánchez GA, Bernad-Bernad MJ and Santisteban RG. **Subconjunctivally injected liposome encapsulated sirolimus and topical tacrolimus for the treatment of non-responsive keratoconjunctivitis sicca in the spontaneous dog model.** *Vet Med Anim Sci.* 2018; **6**:1. <http://dx.doi.org/10.7243/2054-3425-6-1>